
Benign Infectious Lesions/Conditions of the Oral Mucous Membrane

Herpes simplex virus infection

Herpes zoster

Candidiasis

Angular cheilitis

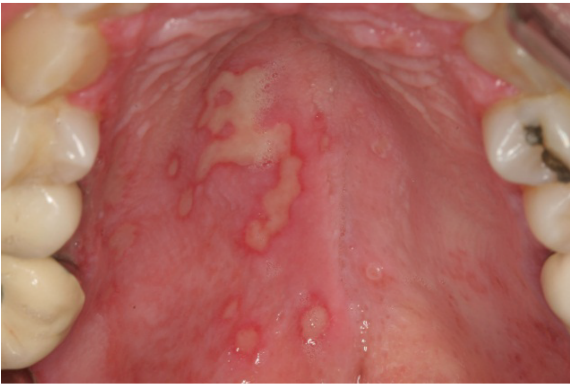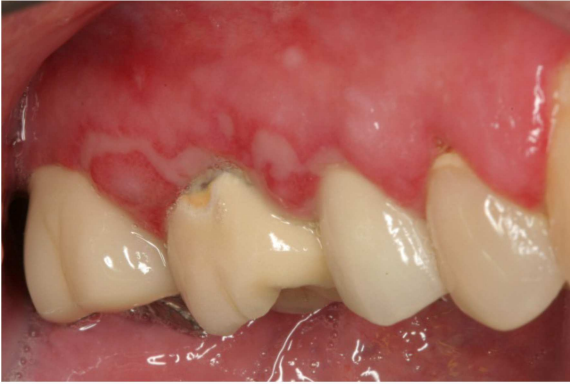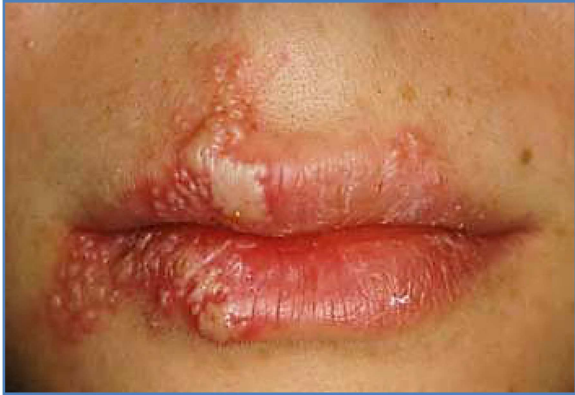Atrophic glossitis

1. Herpes simplex virus infection

Description: Herpes simplex infection is a common disease that, when clinical signs are present, show striking and distinct oral features. The infection shows two clinical presentations: primary and secondary, or recurrent. Primary herpes simplex: Most primary infections are asymptomatic and occur during childhood. When symptoms occur, clinical features include fever, malaise and tender lymphadenopathy. Oral manifestations are characterized by painful ulcerations that involve both keratinized and nonkeratinized mucosal surfaces (gingivostomatitis). A “punched out” gingival margin is often characteristic. Occasionally, the infection occurs later in life and in an adult may manifest as a pharyngotonsillitis. Patients are typically symptomatic from 1-2 weeks.

Secondary or recurrent herpes simplex: Recurrent herpes affects a small number of patients infected with the virus. Most recurrent lesions affect the vermillion zone of the lip (recurrent herpes labialis). Intraoral lesions are typically limited to the keratinized mucosa and are typically only mildly symptomatic, in contrast to those of the primary outbreak. Recurrent herpes labialis may occur spontaneously or be triggered by such stimuli as sunlight, trauma or systemic infection. It often begins with a prodromal period of a few hours and is characterized by a “tingling” or “itching” sensation. The outbreak progresses to the development of numerous vesicles, which quickly rupture, leaving an amber or honey-colored crust. In the immune competent, lesions heal within a week to 10 days. The frequency of outbreaks is highly variable from patient to patient, with some experiencing recurrences quite regularly.

Etiology: Oral infection is caused by members of the human herpesvirus (HHV) family, herpes simplex type 1 (HSV-1, HHV-1) or, to a lesser extent, herpes simplex type 2 (HSV-2, HHV-2).



Treatment: The primary infection may be treated effectively by NSAIDs and antiviral medications if administered within the initial 72 hours. Topical anesthetics may also be effective in reducing the discomfort. It is necessary for patients to maintain adequate hydration.

Recurrent herpes infection may also be treated effectively, if therapy is initiated at the earliest point of the outbreak. A regimen of high-dose, short duration valacyclovir has shown some efficacy, even aborting the outbreak in some patients when initiated during the prodromal period. Topical antiviral medications may also shorten the duration of the outbreak.

Prognosis: The prognosis is good, with most outbreaks self-limiting. For the immunocompromised patient, however, the infection may be characterized by substantial morbidity, necessitating early therapeutic intervention.

Differential diagnosis: Herpes simplex is often distinct in its presentation and readily diagnosed. For milder cases, or those without significant oral ulceration, infectious mononucleosis may be considered, since tender lymphadenopathy is often a component of both diseases. Other considerations might include hand, foot and mouth disease, herpangina or erythema multiforme.

2. Herpes zoster

Description: Herpes zoster is the recurrent outbreak associated with the virus that causes chicken pox. The virus is a member of the human herpesvirus family and, like other herpes viruses, primary infection ends in latency. Often after many years or decades, the recurrent outbreak is manifested as herpes zoster. Unlike HSV-1, the recurrence is typically limited to a single outbreak. After resolution of the primary varicella-zoster infection, the virus resides in the dorsal spinal ganglia. Herpes zoster will involve the dermatome supplied by the sensory nerves. Often, a painful prodrome will develop prior to the vesicular outbreak. Lesions are intensely painful and typically show an abruptly unilateral distribution. The vesicles rupture, leaving a crust which will usually heal in 2-3 weeks. While symptoms typically resolve along with resolution of the exanthem, a number of unfortunate patients continue to experience pain, a condition known as post-herpetic neuralgia. Ocular involvement is associated with significant morbidity.

The oral lesions or herpes zoster will follow a similar unilateral anatomic distribution and be characterized by painful ulcerations of the mucosa.

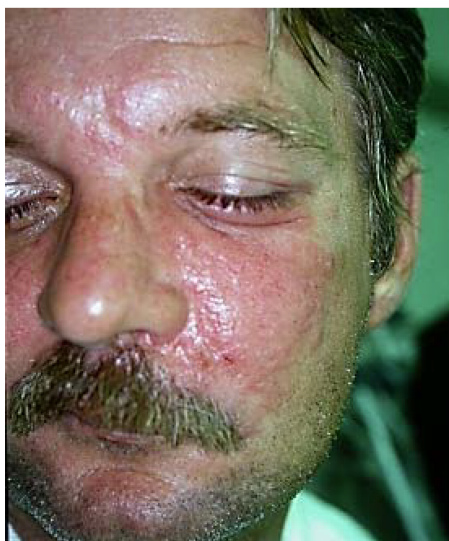Etiology: Herpes zoster is caused by the varicella-zoster virus (VZV), a member of the human herpesvirus family (HHV-3).

Treatment: A vaccine for herpes zoster is currently available and recommended for those with a history of varicella-zoster infection. For those experiencing the recurrence, antiviral medications are sometimes effective in shortening the duration of the outbreak, especially when initiated within the first 3 days. For post-herpetic neuralgia, topical Capsaicin has shown some

efficacy. Other therapeutic regimens may include systemic medications such as tricyclic antidepressants, anticonvulsants or gabapentin.

Prognosis: For the immune competent and those spared post-herpetic neuralgia, the prognosis is generally favorable. For the immunocompromised, herpes zoster can be associated with significant morbidity. Post-herpetic neuralgia can also be problematic for a year or more in a small percentage of patients.

Differential diagnosis: The distribution of lesions is often diagnostic for herpes zoster. However, in mild cases, the symptoms may mimic neurological conditions such as trigeminal neuralgia. Contact dermatitis may also be considered, although the discomfort associated with herpes zoster is not typically associated with this condition.



3. Candidiasis

Description: Candidiasis refers to infection with the dimorphic fungal organism, *Candida albicans*. The infection is primarily superficial, although rare invasive or disseminated cases may be seen in the severely immunocompromised. The organism normally resides as a yeast in a substantial percentage of the population. Under conditions favorable to the organism, such as broad spectrum antibiotic therapy, corticosteroid therapy or xerostomia, transformation to the hyphael form and progression to an infectious state may occur. Candidiasis infection most often occurs in one of four clinical presentations: pseudomembranous, or “thrush;” erythematous, which may include denture stomatitis; hyperplastic; and angular cheilitis (next topic).

Pseudomembranous candidiasis: sometimes known as “thrush,” is characterized by the development of white, curd- or plaque-like deposits that are easily removable. While underlying erythema may be seen, ulceration is rare. Patients may complain of sensitivity to spicy foods or bad taste, but symptoms are typically mild. Pseudomembranous candidiasis is seen most commonly in infants, the immunocompromised or patients undergoing corticosteroid therapy.

Erythematous candidiasis: is simply characterized by erythema and shows a number of recognized forms, including denture stomatitis and central papillary atrophy. Denture stomatitis is seen in patients with removable prostheses. The area covered by the prosthesis is erythematous and tends to clearly follow the outline of the denture or partial denture. Typically asymptomatic, denture stomatitis is often diagnosed during routine dental visits. Contributing factors to the development of denture stomatitis include xerostomia, 24 hour denture wear and/or poor denture hygiene.

Central papillary atrophy: was previously diagnosed under the term median rhomboid glossitis and thought to represent a developmental abnormality of the dorsal surface of the tongue. It is characterized by a variably-sized area of papillary atrophy and erythema. It is often asymptomatic, although patients may complain of sensitivity to spicy foods. Long-term cases may show an inflammatory hyperplastic response of the oral mucosa. Without treatment, the area of papillary atrophy may progress to involve the entire dorsal surface of the tongue. Contributing factors are similar to other forms of candidiasis.

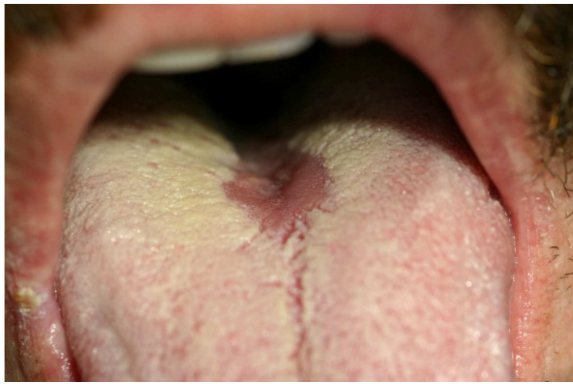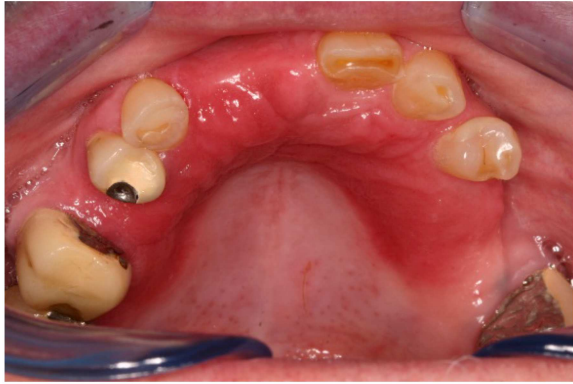
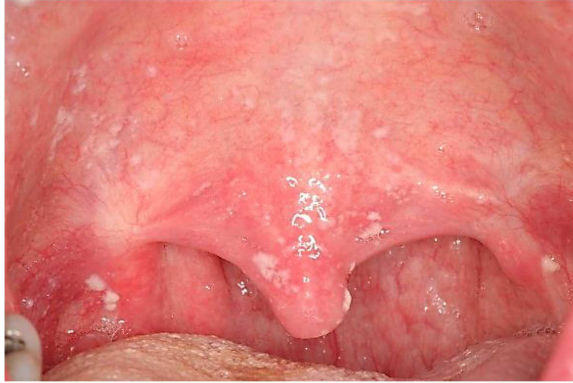
Hyperplastic candidiasis (candidal leukoplakia): is an uncommon form of infection that may be difficult to differentiate from the more serious process, leukoplakia. It is characterized by a white plaque that cannot be removed. While any mucosal surface may be involved, the anterior buccal mucosa is a relatively common site. Antifungal therapy is often necessary to rule out preneoplasia.

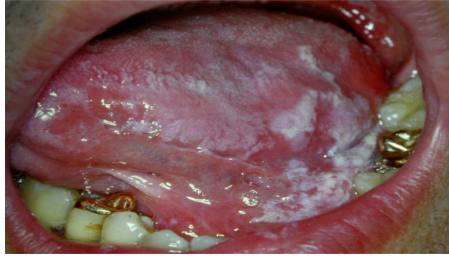Etiology: Most candidiasis infections are associated with *Candida albicans*.

Treatment: Typically, outbreaks are superficial and effectively treated with topical antifungal agents such as Nystatin oral suspension or clotrimazole oral troches. Systemic agents, such as fluconazole, may be used in patients who experience recurrences or in cases that are refractory to the standard treatments. It is important to remember that the treatment of denture stomatitis is not limited to elimination of the organism from the oral cavity. Disinfection of the prosthesis is also necessary to reduce the potential for recurrence.

Prognosis: The prognosis for most patients is excellent. For the immunocompromised, the prognosis is more dependent upon their immune status than candidiasis infection.

Differential diagnosis: It may be necessary to differentiate denture stomatitis from allergy to dental materials. However, a thorough clinical history will often assist the clinician in differentiating the two conditions. Hyperplastic candidiasis is often difficult to differentiate from the more serious premalignant lesion, leukoplakia. For these patients, re-evaluation after appropriate antifungal therapy will typically result in the accurate diagnosis.





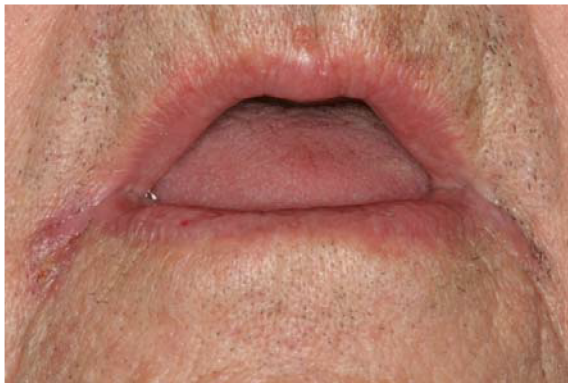4. Angular cheilitis

Description: Angular cheilitis is a chronic condition affecting the commissural areas of the mouth. It is within the spectrum of diseases associated with candidiasis infection, although a concomitant bacterial component is often present. The lesions of angular cheilitis present as ulceration or cracking at the commissures. Lesions have a tendency to wax and wane, although they may be present for years without treatment. Contributing factors are similar to those of other forms of candidiasis infection. A reduced vertical dimension of occlusion may also be a contributing factor.

Etiology: *Candida albicans*, often in combination with staphylococcal component.

Treatment: Topical agents, such as a formulation of hydrocortisone and iodoquinol, are often effective in resolving the lesions of angular cheilitis.

Prognosis: Excellent



Differential diagnosis: The condition is typically unique in its presentation and easily diagnosed based upon the clinical features. Some vitamin or iron deficiencies are sometimes associated with a similar clinical presentation.

5. Atrophic glossitis

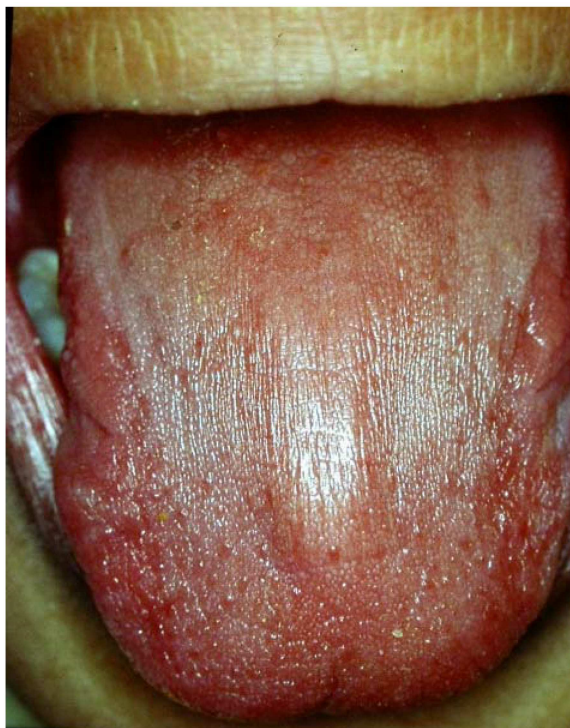Description: Atrophic glossitis, also known as “smooth tongue” is one of the most frequent tongue conditions associated with systemic disease and requires thorough evaluation. The mucosa of the tongue is characterized by a smooth appearance, which is due to atrophy of filiform papillae, with an underlying pink to reddish color and may be painful.

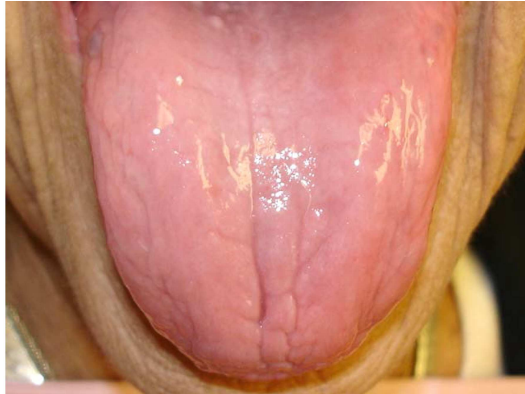Etiology: Atrophic glossitis may be due to xerostomia, with or without co-existing candidiasis, that is often caused by medication use or a systemic disease such as Sjogren’s disease. Other causes include deficiencies of Vitamin B, folic acid, niacin, riboflavin, or iron. Systemic diseases associated with atrophic glossitis include sarcoidosis, syphilis, kwashiorkor and celiac disease. It may also be associated with medication use, such as antibiotics or inhaled corticosteroids used for treatment of asthma which can lead to Candida infection.

Treatment: Treatment is aimed at elimination or palliation of the underlying condition.

Prognosis: The prognosis is good with treatment of the underlying condition.

Differential diagnosis: Median rhomboid glossitis, geographic tongue, strawberry tongue (Scarlet fever)





Candidiasis/denture stomatitis: Oral candidiasis, a fungal infection is a very common complication of dry mouth. The decreased amount of saliva and protecting factors change the local immunity of the oral tissues facilitating the overgrowth of the fungus. *C. albicans* is the most common specie. Ill-fitting dentures can facilitate the overgrowth of fungus. Figure ... shows a common presentation of denture stomatitis. In patients with dry mouth, wearing dentures may be difficult. Saliva is an important vehicle in the process of denture retention in the oral cavity.

Additional reading

Atrophic glossitis

Erriu M, Canargiu F, Orru G, Garau V, Montaldo C, Idiopathic atrophic glossitis as the only clinical sign for celiac disease diagnosis: a case report. *J Med Case Rep.*2012, 6: 185.

Reamy BV, Derby R, Bunt CW, Common tongue conditions in primary care. *Am Fam Physician.* 2010, 81:627-634.

Terai H, Shimahara M, Atrophic tongue associated with *Candida*. *J Oral Pathol Med* 2005 34: 397-400

Herpes simplex virus infection

Neville BW, Damm DD, Allen CM, Bouquot JE. *Oral and Maxillofacial Pathology.* 3rd ed. Saunders 2009.

Raborn GW, Grace MGA. Recurrent herpes simplex labialis: selected therapeutic options. *J Can Dent Assoc* 69:498-503, 2003

Stoopler ET, Greenberg MS. Update on herpesvirus infections. *Dent Clin North Am* 47:517-532, 2003

Herpes zoster

Barrett AP, Katelaris CH, Morris JGL et al. Zoster sine herpette of the trigeminal nerve. *Oral Surg Oral Med Oral Pathol* 75:173-175, 1993.

Straus SE, Ostrove JM, Inchauspe G et al. NIH conference. Varicella-zoster virus infections. Biology, natural history, treatment and prevention. *Ann Intern Med* 108:221-237, 1988.

Candidiasis/angular cheilitis

Akpan A, Morgan R. Oral candidiasis. *Postgrad Med J* 78:455-459, 2002.

Neville BW, Damm DD, Allen CM, Bouquot JE. *Oral and Maxillofacial Pathology*. 3rd ed. Saunders 2009.

Samaranayake LP, Cheung LK, Samaranayake YH. Candidiasis and other fungal diseases of the mouth. *Dermatol Ther* 15:251-269, 2002.